

MU VMDL Newsletter

IN THIS ISSUE

New Faculty Member
AAVLD Conference
Testing News
Residency Programs Update

Doc Fales Honored
New Portal
What Is Your Diagnosis?



Veterinary Medical
Diagnostic Laboratory
Veterinary Health Center
University of Missouri

A MESSAGE FROM THE DIRECTOR

The Veterinary Medical Diagnostic Laboratory (VMDL) has received a five-year full accreditation from American Association of Veterinary Laboratory Diagnosticians (AAVLD). AAVLD accreditation ensures that the VMDL's test results are reliable, standardized protocols are used, procedures are documented, and international audits are conducted regularly. The test results generated by an AAVLD-accredited lab are accepted by other countries for live animal or animal products export, which is critical to the success of Missouri's animal agriculture. It would not have been possible to achieve this goal without the support of clients, alumni and the Missouri Department of Agriculture. I especially thank the stakeholders who traveled to Columbia in late June to meet the AAVLD site visit team and spoke on behalf of the VMDL and Missouri.

In addition to preparing for the AAVLD site visit, the VMDL has been updating its laboratory information management system. In August we switched to a new, more efficient system called VetView. The dedication of our CVM IT group and Angela Royal's leadership made the transition successful. VetView changed the look of the VMDL portal, but not clients' online access to test results. The online payment center is also available. If you need help in signing up for online review of lab results, please contact us.



This has been a busy year for the VMDL. Recently, we developed or validated several diagnostic tests. The VMDL now offers *Cryptosporidium* oocysts and *Giardia* cysts FA, Canine Antibody Titer Check, and Senecavirus A PCR. SVA infection in swine causes snout and coronary band vesicles, known as idiopathic vesicular disease in swine. Since the vesicles are indistinguishable from FMDV, vesicular stomatitis virus (VSV), and swine vesicular disease, a foreign animal disease investigation is conducted by state and federal agencies. To provide a quick differential diagnosis to the producers, the VMDL runs FMD, SVA and VSV on the same day of sample submission.

Best regards,
*Dr. Shuping Zhang, Director,
Veterinary Medical Diagnostic Laboratory
Professor, Department of Veterinary Pathobiology*

VMDL MISSION STATEMENT

- To provide appropriate and timely diagnostic support to veterinary practitioners, livestock and poultry interests, companion animal interests, wildlife conservationists and state-federal regulatory officials.
- To monitor domestic animals, indigenous wildlife and zoo animals for diseases that are a threat to livestock health and public health.
- To support the teaching mission of the College of Veterinary Medicine.
- To create new knowledge through fundamental and translational research.

The VMDL is committed to all aspects of our mission statement, including our important role in biosecurity. As an AAVLD-accredited laboratory working within the National Animal Health Laboratory Network, the VMDL will be called upon to provide testing services in the face of suspected or confirmed foreign animal, zoonotic, and/or economically important disease outbreaks.

MU VMDL Newsletter

NEWS BRIEFS



Wole Odemuyiwa, DVM, PhD, DACVM

VMDL welcomes new faculty in molecular diagnostics

Welcome to Wole Odemuyiwa, DVM, PhD, DACVM, our new head of molecular diagnostics. Wole hopes to continue the current high standard of diagnostic work in the VMDL and develop new tests that will expand our current offerings in molecular diagnostics. His research will focus on how pathogens interact with their hosts, and how previously unknown viral diseases emerge.

VMDL well-represented at annual AAVLD conference

Multiple members of the VMDL faculty and staff had the opportunity to attend the 59th annual AAVLD conference in Greensboro, North Carolina, in October. Gayle Johnson, Tom Reilly and Susan Martin delivered presentations on pathology, bacteriology and quality assurance topics.

New serology test assesses for two organisms

Our serology section now offers a combined *Cryptosporidium*/*Giardia* FA test.

Simply submit a fecal sample or intestinal scraping sample and we can assess for both of these organisms for \$26. Turn-around time is two to three business days.

Combined test offers fixed price option

On our submission forms you will now see a new bacteriology test combination. This option includes up to three susceptibilities on organisms recovered via aerobic culture for \$100. Selecting this route will improve turnaround time and allow you to charge a fixed price for your clients up front. Our standard options for culture and susceptibilities are still available, should those suit your needs better.

Clinical and anatomic residency programs update

Two of our residents successfully completed training programs late this summer. Holly Taylor and Diana Hoffman completed their residencies in anatomic and clinical pathology, respectively. Taylor is now employed as a pathologist at Wisconsin Veterinary Diagnostic Laboratory in Barrow, Wisconsin, and Hoffman has returned to active duty military service (Army) and is currently chief of diagnostics at the Department of Defense Food Analysis and Diagnostics Laboratory, Fort Sam Houston, Texas. We work closely with our residents during their three-year terms, so it is always bittersweet to see them leave the nest.

The VMDL prides itself on our robust pathology training programs, and two new residents have begun their tenure with us. Tatiana Rothacker, who earned her DVM at MU in 2015, is our newest clinical pathology resident, joining our current second- and third- year residents.

Mike Zinn, who earned his DVM at Colorado State University in 2008, has joined our anatomic pathology team including our current second-year resident.



William Shore, DVM, chairman of the MVMA Foundation, reads the nomination of William Fales to the Missouri Veterinary Medical Foundation Veterinary Honor Roll.

Professor Emeritus William Fales honored

MU College of Veterinary Medicine Professor Emeritus William H. Fales, PhD, was inducted into the Missouri Veterinary Medical Foundation (MVMF) Veterinary Honor Roll on Sept. 10.

The Veterinary Honor Roll recognizes veterinarians who have been nominated for inclusion by people whose lives they have touched. Fales is the only individual who is not a doctor of veterinary medicine ever to be inducted. MVMF Board members nominated him for inclusion. Fales is also the only non-DVM to be an active voting member of the MVMA. He was elected to full membership in the MVMA in 1991 and was elected to honorary membership in the Missouri Academy of Veterinary Practice in 1999.

Congratulations, Dr. Fales! This is a well-deserved honor and we are proud to have you as a colleague in the VMDL!

NEWS BRIEFS

VMDL has updated portal site for clients

We have transitioned to a new laboratory information system, VetView, and accordingly have a new lab portal. Of note, the Veterinary Health Center hospital portal remains unchanged until sometime in 2017.


For those unfamiliar with the lab portal, this is a secure online tool for you to access laboratory reports and invoices. You can log in and check the status of pending laboratory tests, re-print old laboratory reports, and access invoices as needed.

Any VMDL clinic or business can gain free access to the portal by registering at vetview.cvm.missouri.edu/login/auth. Previous users of the old portal site will simply need to enter their old username and then click "reset password." A link with instructions will be sent to you on how to gain access using the new technology.

How to Locate, View and Print Results from the New Portal

Once logged in you will see the following options at the top of the screen: Home, Catalog, Accessions, Patients and Invoices. Through the Accessions tab you can search by accession number, patient name, case number, client name, or date the sample was received at our lab. You can find more specific instructions on the VMDL website at vmdl.missouri.edu/docs/vmdlportalinstructions.pdf

Answers are on
Page 4.



Across

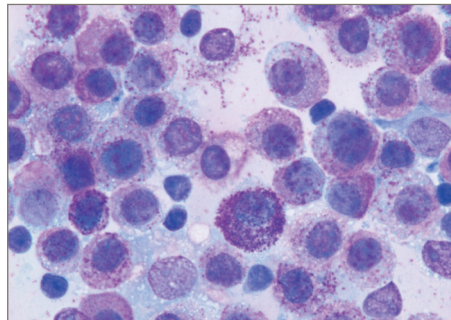
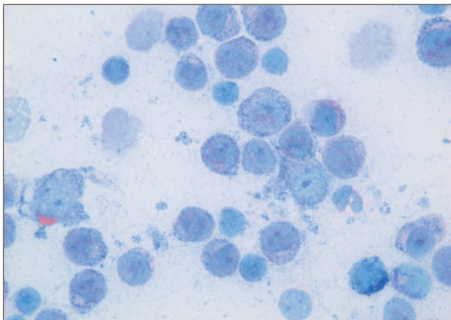
4. Director of the VMDL (first and last name)
5. Specimen of choice for Pseudorabies ELISA
8. Negatively staining bacteria
10. We have a new combined serology test to assess for both Cryptosporidium and
11. A clinical or anatomic pathology residency generally takes this many years to complete
12. DNA sequence amplification laboratory technique
13. A dog with zinc toxicity will likely have this microscopic change to RBCs (two words)
15. Standard operating procedure
16. Use of antibodies to highlight specific proteins on biopsy slides
18. Anticoagulant used for routine hematology testing
19. You wouldn't want to eat off of this dish
21. Clinical pathology lab supervisor (first and last name)
23. Checking for distant migration of tumor cells
25. Recently inducted into the MVMA Hall of Fame (first and last name)

Down

1. These bacteria are very small and pleomorphic, sometimes forming rings or c-shapes
2. Caseous lymphadenitis is caused by this organism (genus only)
3. Blue, round, broad-based budding yeast
6. Number of genera identified with our tick-borne disease PCR panel
7. These cells are round with purple granules
8. This cell is a "big eater"
9. A Moroccan leather appearance of the abomasal mucosa suggests infestation with
14. "Idiopathic" Swine Vesicular Disease is caused by
17. Infectious laryngotracheitis is caused by a
20. This type of blood sample should be used for lead testing (two words)
22. Silver stain which highlights fungal agents
24. VMDL recently attained full accreditation by the

MU VMDL Newsletter

WHAT IS YOUR DIAGNOSIS?



(Left) This is an aspirate of an enlarged mandibular lymph node from a cat that also has multiple dermal masses. This is what we see through the 100x objective on a Diff Quik stained slide and in some areas of a Wright-Giemsa stained slide. (Right) Upon scanning for better-stained areas of this slide, we find areas like this.

This case highlights the potential variability in mast cell granule staining intensity. Diff Quik and other aqueous (rather than methanolic) stains may fail to adequately stain mast cell granules, yielding a population of round cells con-

taining moderate to abundant amounts of clear cytoplasm. Sometimes intermixed eosinophils may offer a clue that the pale round cells may in fact be mast cells, but not all mast cell neoplasms contain an eosinophilic infiltrate.

Answer: Mast cell neoplasia, presumably metastatic.

It is important to scan cytology sample slides thoroughly to identify well-preserved and well-stained cells for interpretation. In this case the thinner areas of the lymph node aspirate stained with methanolic Wright-Giemsa revealed abundant mast cells with typical purple cytoplasmic granules. The patient had multiple dermal foci of mast cell neoplasia with metastasis to this mandibular lymph node.

We encourage clients to include one or more unstained and unfixed blood smear or cytology slides in addition to any stained slides for evaluation in our clinical pathology lab. Our automated stainer utilizes a methanolic Wright Giemsa stain and thus is more likely to stain mast cell, basophil, and granular lymphocyte granules, as compared to aqueous quick stains.

CROSSWORD ANSWERS

Across:

4. Shuping Zhang
5. Serum
8. Mycobacterium
10. Giardia
11. Three
12. PCR
13. Heinz bodies
15. SOP
16. Immunohistochemistry
18. EDTA
19. Petri
21. Cheryl Rojas
23. Staging
25. Bill Fales

Down:

1. Mycoplasma
2. Corynebacterium
3. Blastomyces
6. Four
7. Mast
8. Macrophage
9. Ostertagia
14. Senecavirus A
17. Herpesvirus
20. Whole blood
22. GMS
24. AAVLD

